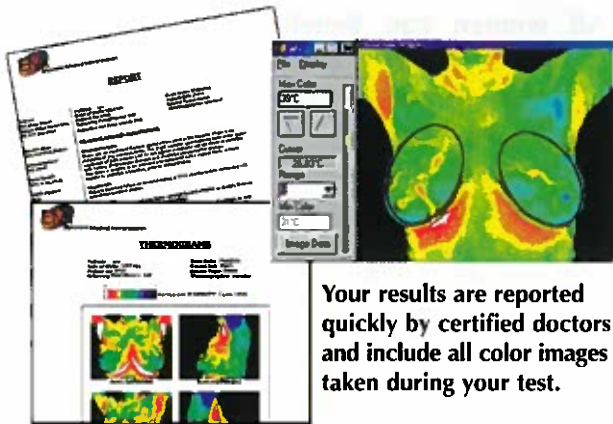


Meditherm DITI

An extremely valuable test to help in the early detection of breast disease.



Your results are reported quickly by certified doctors and include all color images taken during your test.

Current Early Detection Guidelines

One day there may be a single method for the early detection of breast cancer. Until then, using a combination of methods will increase your chances of detecting cancer in an early stage. These methods include :

- Annual DITI screening for women of all ages.
- Mammography, when considered appropriate for women who are aged 50 or older.
- A regular breast examination by a health professional.
- Monthly breast self-examination.
- Personal awareness for changes in the breasts.
- Readiness to discuss quickly any such changes with a doctor.

These guidelines should be considered along with your background and medical history.

“Early Detection Saves Lives”

DITI's role in breast cancer and other breast disorders is to help in early detection and monitoring of abnormal physiology and the establishment of risk factors for the development or existence of cancer. When used with other procedures the best possible evaluation of breast health is made.

Increase your chances of detecting breast cancer in its earliest stages.

For information and appointments please contact:



Meditherm®
Digital Infrared Thermal Imaging

DITI Imaging
(210)705-1232 • (866)409-2506
www.ditiimaging.com

www.meditherm.com/breasthealth

DITI has been recognized as a viable diagnostic tool since 1987 by the AMA Council on Scientific Affairs, the ACA Council on Diagnostic Imaging, the Congress of Neuro-Surgeons in 1988 and in 1990 by the American Academy of Physical Medicine and Rehabilitation.

© Copyright Meditherm Inc. 2003

BREAST HEALTH



What is DITI?

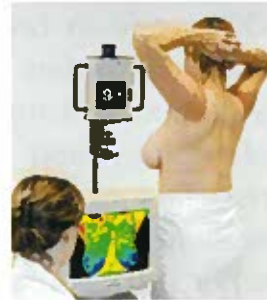Digital Infrared Thermal Imaging 'DITI' is a 15 minute non invasive test of physiology. It is a valuable procedure for alerting your doctor to changes that can indicate early stage breast disease.

The benefit of DITI testing is that it offers the opportunity of earlier detection of breast disease than has been possible through breast self examination, doctor examination or mammography alone.

DITI detects the subtle physiologic changes that accompany breast pathology, whether it is cancer, fibrocystic disease, an infection or a vascular disease. Your doctor can then plan accordingly and lay out a careful program to further diagnose and /or MONITOR you during and after any treatment.

PROCEDURE

- **Non invasive**
- **No radiation**
- **Painless**
- **No contact with the body**
- **F.D.A registered**



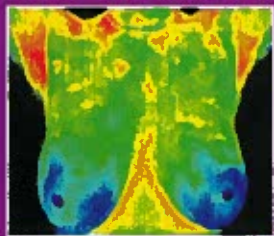
This quick and easy test starts with your medical history being taken before you partially disrobe for the scanning to be performed. This first session provides the baseline of your "thermal signature". **A subsequent session assures that the patterns remain unchanged.**

All of your thermograms (breast images) are kept on record and once your stable thermal pattern has been established any changes can be detected during your routine annual studies.

WHO?

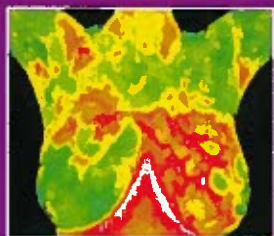
All women can benefit from DITI breast screening. However, it is especially appropriate for younger women (30 - 50) whose denser breast tissue makes it more difficult for mammography to be effective. Also for women of all ages who, for many reasons, are unable to undergo routine mammography. This test can provide a 'clinical marker' to the doctor or mammographer that a specific area of the breast needs particularly close examination.

It takes years for a tumor to grow thus the earliest possible indication of abnormality is needed to allow for the earliest possible treatment and intervention. DITI's role in monitoring breast health is to help in early detection and monitoring of abnormal physiology.




NORMAL

Good thermal symmetry with no suspicious thermal findings. These patterns represent a baseline that won't alter over time and can only be changed by pathology.



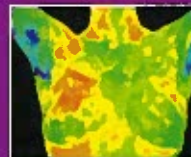
FIBROCYSTIC

Significant vascular activity in the left breast which was clinically correlated with fibrocystic changes.



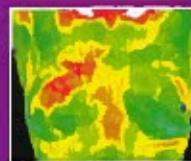
BASELINE

Baseline thermogram showed a slight hyperthermic asymmetry in the upper right breast.



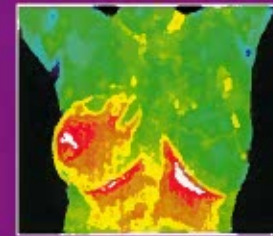
3 MONTHS

The follow-up study at 3 months showed the pattern had become more well defined. Mammography was inconclusive.



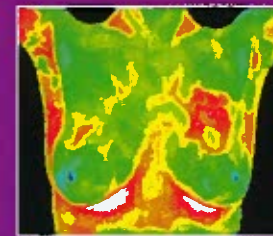
12 MONTHS

Significantly increased vascular changes. Repeat mammogram showed a small calcification (1 mm) at 1 O'clock. A lumpectomy was performed confirming a malignant carcinoma (DCIS).



INFLAMMATORY CANCER

There were no visible signs of abnormality. Referral to a breast specialist and a subsequent biopsy diagnosed inflammatory breast cancer at a very early stage.



DUCTAL CARCINOMA

The vascular asymmetry in the upper left breast was particularly suspicious and clinical investigation indicated a palpable mass. A biopsy was performed and a DCIS of 2 cm was diagnosed.